

# SRA COMMUNITY INVOLVEMENT



Attendees to the 20th Annual Texas Lunar New Year Celebration in Houston were treated to Red Tote Bags donated by SRA in partnership with Memorial Hermann Southwest Hospital


In addition to providing our patients and the medical communities we serve with the highest caliber radiology services available, Synergy Radiology Associates is also committed to being an active part of the community. SRA has continued to demonstrate this commitment in 2016 through our involvement in several recent events, including a community festival, 5K fun run and a sporting clay tournament.

SRA participated in the 20th Annual **Texas Lunar New Year Celebration** on February 13, partnering with Memorial Hermann Southwest Hospital to provide red tote bags for guests attending the annual event. Held in downtown Houston for the past 19 years, this colorful event celebrates the Asian Lunar New Year and reflects the diversity and leadership of the greater Asian community while fostering friendship among all cultures.



Physician Relations Representative Samantha Bond (Left) and diagnostic radiologist Terence O'Connor, M.D. represented SRA in the 5K run benefiting the Cy-Fair Educational Foundation and raising awareness of the new Memorial Hermann Convenient Care Center in Cypress.

On February 27, two Synergy Radiology staffers put on their running shoes and participated in the **Third Annual Superintendent's Fun Run**. SRA Physician Liaison Samantha Bond and radiologist Terence O'Connor participated in the event, staged at the Berry Center in the Towne Lake community. The 5K run benefited the Cy-Fair Educational Foundation and helped to raise awareness of the new Memorial Hermann Convenient Care Center in Cypress (CCC). The event raised \$52,000 for the Cy-Fair Educational Foundation.

During another community event, SRA sponsored a team and two support stations at the **Memorial Hermann Annual Heroes in Health Sporting Clay Shoot** on February 29. The tournament was held at the Greater Houston Gun Club to benefit the Memorial Hermann Life Flight<sup>®</sup> critical care air ambulance service that transports critically ill and injured patients in the greater Houston area. Life Flight is a community service of Memorial Hermann that operates as a hospital-based, non-profit organization, relying on community support and fundraising to support its operations. 



(Left to right) Jared Moore; Dr. Armando Saenz; Dr. William Pfeiffer; Dr. Walid Adham at the Memorial Hermann Annual Heroes in Health Sporting Clay Shoot



Emily Cortez, Physician Relations Representative, holding down the SRA fort (tent) at the Memorial Hermann Annual Heroes in Health Sporting Clay Shoot

# SYNERGY REPORT

## TOTALLY RAD NEWS:

### Are You Happy with the Gray Matter Volume in Your Precuneus?

*Structural MRI highlights the fountain of happiness*

Ever wonder what makes you happy and why? Researchers at Kyoto University in Kyoto, Japan, think they've got a pretty good idea, and they're talking about it in recently published research showing how gray matter volume in the precuneus region of the brain is significantly associated with happiness. We're guessing the researchers are quite happy with their research, unless, that is, they are somewhat lacking in the precuneus gray matter category.

Reaching back as far as the Greek philosopher Aristotle, humans have pondered the true nature of happiness. Thousands of psychological studies have looked into the concept of happiness, and in recent years the advent of functional MRI has enabled researchers to see areas of the brain that are activated by experiences that subjectively "make us happy." However, until now, no studies looking into the neural substrates of subjective happiness using structural MRI (to provide a complementary objective measure of happiness) had been performed.

Using a Siemens MAGNETOM Trio 3T for structural MRI combined with psychological questionnaires, Wataru Sato and colleagues reported<sup>1</sup> a positive relationship between the subjective happiness score (derived from the well-validated Subjective Happiness Scale) and gray matter volume in the right precuneus<sup>2</sup> – a focal point of activity in fMRI studies of happiness. Located in the posteromedial portion of the parietal lobe, the precuneus is responsible for a wide range of higher-order cognitive functions, including visuo-spatial imagery, episodic memory retrieval and self-processing operations.<sup>3</sup>

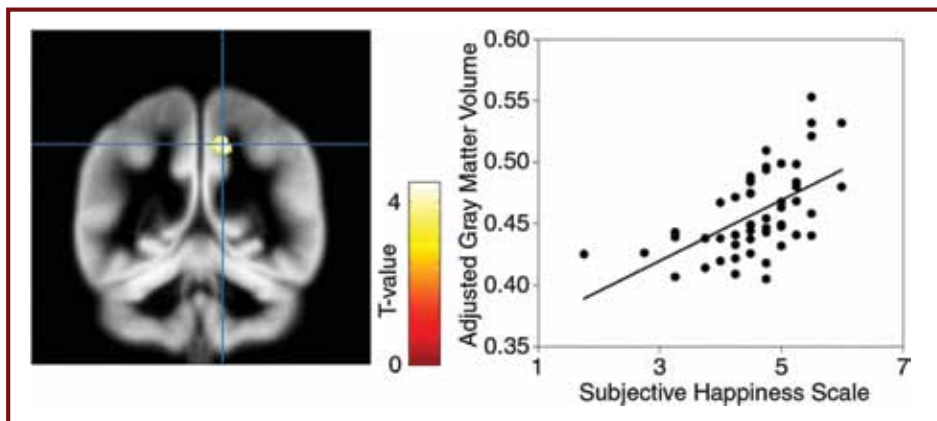



Figure 1. Brain region significantly associated with the subjective happiness score. (Left) A statistical parametric map ( $p < 0.001$ , peak-level uncorrected for display purposes). The area is overlaid on the spatially normalized gray matter tissue probability map. The blue cross indicates the location of the peak voxel. The red-white color scale indicates the T-value. (Right) A scatter plot of the adjusted gray matter volume as a function of the subjective happiness score at the peak voxel.

NOTE: Figure 1 is used under the Sato et al. article's Creative Commons license; to view a copy of this license, visit [creativecommons.org/licenses/by/4.0/](http://creativecommons.org/licenses/by/4.0/)

(continued on inside)



### *In this issue*

Check out our Totally Rad News about a new study that uses structural MRI to pinpoint the "fountain of happiness" in our brains

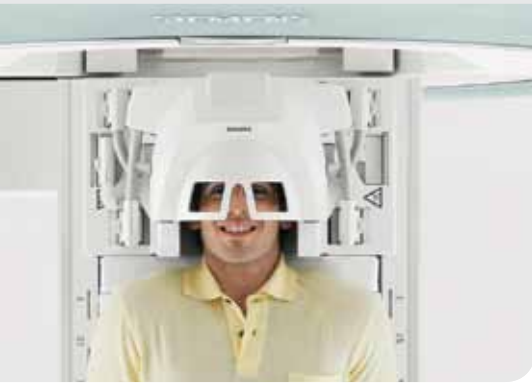More than just imaging: SRA subspecialty trained radiologists provide more than 30 vascular and Interventional radiology services

From a New Year's celebration to a fun run and sporting clay shoot, SRA has been very active in our community!

**Physician Spotlight:**  
Faraz Khan, M.D., and his impressive work with the Memorial Hermann Physician Network Radiology Clinical Practice Committee

# TOTALLY RAD NEWS: (continued)

Image scanning was performed using a 3-Tesla scanning system (Siemens MAGNETOM Trio, A Tim System) using a 12-channel head coil. A forehead pad was used to stabilize the head position. A T1-weighted high-resolution anatomical image was obtained using magnetization-prepared rapid-acquisition gradient-echo sequence (repetition time = 2250 ms; echo time = 3.06 ms; inversion time = 1000 ms; flip angle = 9° field of view = 256 × 256 mm; voxel size = 1 × 1 × 1 mm).



Researchers were also happy to report a correlation between the combined Purpose in Life<sup>4</sup> and positive and negative emotional intensity<sup>5</sup> scores, and gray matter volume in the same region. Sato and colleagues suggest the precuneus mediates subjective happiness by integrating the emotional and cognitive components of happiness.

According to a Kyoto University statement, study participants “who scored higher on the happiness surveys had more gray matter mass in the precuneus. In other words, people who feel happiness more intensely, feel sadness less intensely, and are more able to find meaning in life have a larger precuneus.”<sup>6</sup>


All studies have their limitations, and the brain is an extraordinarily complex organ. But this study is exciting because it suggests that more gray matter in a certain area of the brain is an indicator of happiness. Furthermore, just as physical activity can build muscles, researchers’ results suggest that mental training such as meditation can effectively increase gray matter volume in the precuneus which could, therefore, increase happiness. And that is certainly something to be happy about. 🍀

by Daniel J. Snyders, Armada Medical Marketing

- <sup>1</sup> Sato, W. et al. The structural neural substrate of subjective happiness. *Sci. Rep.* 5, 16891; doi: 10.1038/srep16891 (2015).
- <sup>2</sup> Available at: [ppc.sas.upenn.edu/resources/questionnaires-researchers/subjective-happiness-scale](http://ppc.sas.upenn.edu/resources/questionnaires-researchers/subjective-happiness-scale). Accessed March 31, 2016.
- <sup>3</sup> Cavanna AE, Trimble MR. The precuneus: a review of its functional anatomy and behavioral correlates. *Brain*. 2006;129(Pt 3):564-83.

- <sup>4</sup> Available at: [faculty.fortlewis.edu/burke\\_b/personality/pil.pdf](http://faculty.fortlewis.edu/burke_b/personality/pil.pdf) Accessed March 31, 2016.
- <sup>5</sup> Japanese version of the Emotional Intensity Scale (EIS; Bachorowski & Braaten, 1994).
- <sup>6</sup> Available at: [kyoto-u.ac.jp/en/research/research\\_results/2015/151120\\_1.html](http://kyoto-u.ac.jp/en/research/research_results/2015/151120_1.html). Accessed April 1, 2016.

## PHYSICIAN SPOTLIGHT



### Faraz Khan, M.D.

Our physician spotlight in this edition of the Synergy Report is on Faraz Khan, M.D. Specializing in diagnostic and interventional radiology, Dr. Khan has been actively involved in the Memorial Hermann Physician Network (MHMD) Radiology Clinical Practice Committee (CPC) since 2007 and currently serves as the Chair of MHMD’s Radiology CPC,

a position he has held since 2012.

Founded in 1982, MHMD is the largest clinically integrated physician organization in Texas. The Radiology CPC is one of 26 MHMD committees working together to encourage best practices and improve quality care across the entire Memorial Hermann system with streamlined protocols and an evidence-based approach.

As Chair of the CPC, Khan said he is proud of the committee’s recent achievements, including the system-wide standardization of interventional guidelines for radiology procedures and the standardization of protocols and reports for musculoskeletal radiology. The Radiology CPC is currently working on standardization of all radiology reports across the system.

Dr. Khan is board certified by the American Board of Radiology with a Certificate of Added Qualification in Vascular and Interventional Radiology. He earned his medical degree from the University of Texas Medical School at Houston where he subsequently conducted his transitional internship. Dr. Khan served his diagnostic radiology residency and earned his fellowship in interventional radiology at the Mallinckrodt Institute of Radiology at Washington University Medical Center in St. Louis.

According to Dr. Khan, the most rewarding aspect of his work on the radiology CPC is being able to see the big picture.

“Through our committee’s work, I get to interact with other specialties, find out what they’re looking for in radiology and how the hospital system can work together to improve quality patient care as opposed to just looking at our own hospital or our own group,” explained Khan. “I was also fortunate to have taken part in a hospital executive leadership forum, working on a project to improve Medicare profitability across the system while maintaining quality care.”

Dr. Khan is currently looking forward to expanding his work even further, supervising other hospital CPCs beyond radiology, including a supervisory role in the pathology, emergency medicine and perioperative CPCs. 🍀



# VASCULAR AND INTERVENTIONAL RADIOLOGY

With more than 70 board certified and subspecialty trained radiologists, our physician team is experienced at performing minimally invasive interventional radiology (IR) treatments. Augmented by highly skilled clinical staff and support professionals, the level of expertise and patient care we offer is among the highest in Texas, with our ultimate goal being to improve both outcomes and quality of life for the patients you refer and entrust to us.

SRA provides a wide assortment of the latest vascular and interventional treatments and services for numerous medical conditions, including:

## **Embolization**

Embolization techniques employ delivery of clotting agents directly to an area that is bleeding or to block blood flow to a problem area such as an aneurysm or a fibroid tumor. Embolizations performed by a trained interventional radiologist can prevent major open surgeries.

## **Women's Interventional**

### **Uterine Fibroid Embolization**

An embolization procedure of uterine arteries, used by interventional radiologists for benign conditions such as uterine fibroids. It is also performed to stop life-threatening postpartum bleeding, potentially preventing hysterectomy. The procedure uses X-ray to guide small catheters to the arteries to cut off the blood supply to the fibroid or the areas of bleeding.

## **Oncology Interventional**

### **Chemoembolization**

For patients who are not good candidates for standard therapies, chemoembolization offers a method of delivering a relatively large dose of chemotherapy directly to primary or secondary hepatic malignancies. The procedure involves delivering chemotherapeutic drugs via catheter combined with an embolic agent at the site of the tumor. The relative effectiveness of this approach is due to the high concentration of the anti-tumoral drug along with select ischemia at the tumor site.

### **Yttrium-90 (Y-90) Selective Internal Radiation Therapy (SIRT)**

Selective internal radiation therapy (SIRT), also known as radioembolization, involves the injection of radioactive material (Y-90) into the arteries that supply the tumor. This procedure blocks the supply of blood to tumor cells while delivering a high dose of radiation. The procedure can help spare normal tissue and potentially extend the lives of patients with inoperable tumors and improve quality of life.


## **Spine and Joint Interventional**

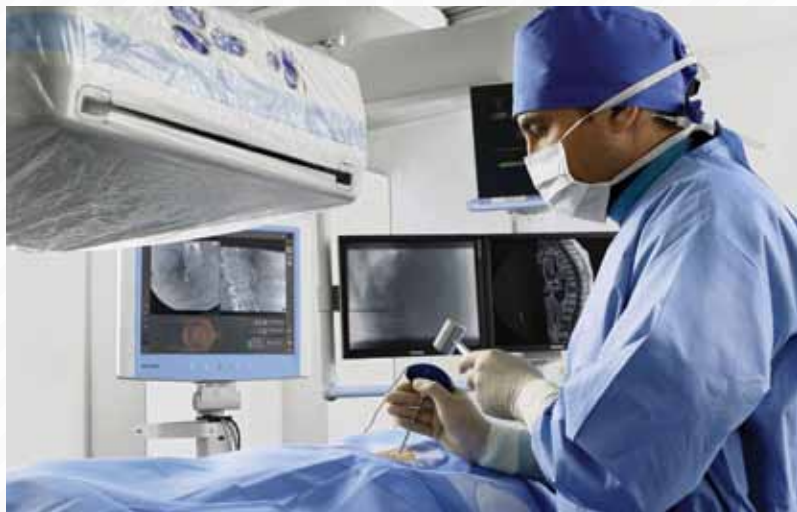### **Kyphoplasty, Vertebroplasty**

Patients with osteoporosis, due to age, chemotherapy or other factors, are at increased risk for painful spine fractures or vertebral compression fractures. Kyphoplasty is a minimally invasive treatment in which medical-grade bone cement is injected directly into the fractured bone.

Vertebroplasty uses a similar method to treat vertebral compression fractures. Bone cement is injected into the spine, which prevents further deterioration and relieves pain in a matter of hours. Both are minimally invasive alternatives to major surgery.

### **Steroid Injections**

These minimally invasive X-ray guided procedures are used to alleviate pain, most often in the spine and joints. Anti-inflammatory agents are injected directly into the targeted area and can be performed in patients who suffer pain caused by bulging disks, stenosis of the spine or post-operative surgery syndromes. Steroid injections can also be used to alleviate degenerative joint pain such as in hips or knees. 



***For more information and a complete list of our minimally invasive treatments, visit the vascular and interventional page on our website at [www.synergyrad.org](http://www.synergyrad.org).***