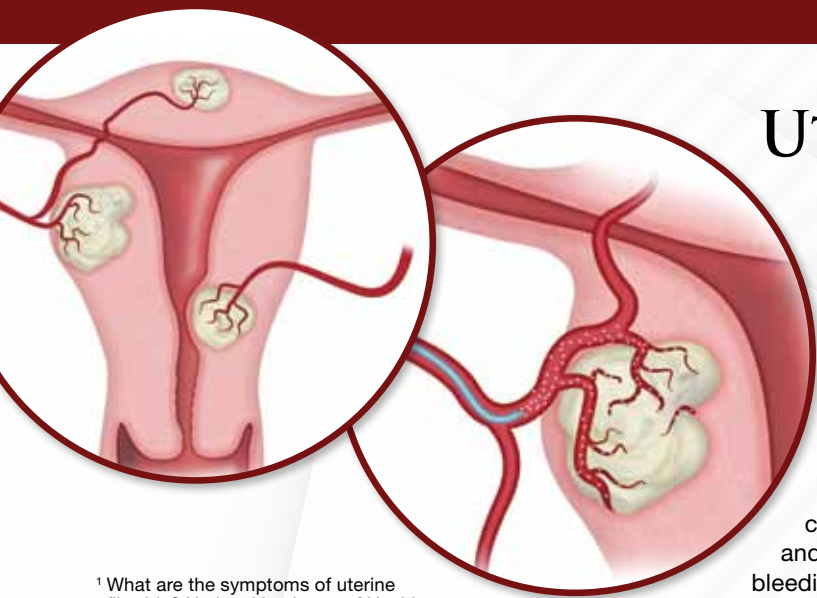

UTERINE FIBROID EMBOLIZATION: a minimally invasive, outpatient alternative to total hysterectomy.

Uterine fibroids, the most common benign tumors in women of childbearing age, can have a major impact on a patient's lifestyle and quality of life. Symptoms may include: painful periods; heavy bleeding that may lead to anemia; pelvic pressure; frequent urination; pain during sex; lower back pain; and reproductive issues such as infertility, multiple miscarriages and early onset of labor during pregnancy.¹

About 40 percent of women develop uterine fibroids by age 35, and more than half of all women will experience uterine fibroids at some time in their lives.² Notably, African-American women are up to three times more likely to have fibroids than Caucasian women, and they tend to show up earlier than in women of other ethnicities. Recent research finds the incidence of uterine fibroids by age 35 was 60 percent among African-American women, increasing to more than 80 percent by age 50.³

Although total abdominal hysterectomy (TAH) remains the most common treatment for symptomatic fibroids, uterine fibroid embolization (UFE) – also referred to as uterine artery embolization (UAE) – is a non-surgical option for patients presenting with symptomatic fibroids.


UFE is an endovascular procedure that shrinks uterine blood vessels via image-guided injection of micro particles. Deprived of blood supply, the fibroids shrink and symptoms are well controlled or eliminated. UFE is performed on an outpatient basis, takes less than an hour, and the patient may return home in less than 24 hours.

In clinical trials and meta-analyses, UFE has been demonstrated safe and effective, as well as cost-effective, with quick recovery times and high levels of patient satisfaction.⁴⁻⁷

Despite this data and the procedure's extensive track record dating back to 1995, recent research presented at the Society of Interventional Radiology (SIR) in Washington, D.C., indicates that UFE is greatly underused as an alternative to TAH in the treatment of uterine fibroids.

SIR reported that UFE is "vastly underutilized, compared to hysterectomies."⁸ From 2012 to 2013, study authors reported 167,650 hysterectomies performed compared to only 2,470 UFEs nationwide.⁹ SIR lists several reasons for the underuse of UFE, including overall lack of awareness and the procedure's requirement for highly trained interventional radiologists and specialized equipment.⁸

UFE is available in the Houston area and performed by our experienced SRA interventional radiologists. Most insurance plans provide benefits for medical coverage, and it is recommended by the American College of Obstetrics and Gynecology as a non-surgical alternative to hysterectomy.

Patient-focused information is available at the SRA Uterine Fibroid Embolization page, and referring physician practices may contact us at 713-621-1103 or visit the SRA physician page. We are always available to consult with referring physicians about UFE or about a patient who may be a candidate for UFE. 

¹ What are the symptoms of uterine fibroids? National Institutes of Health National Institute of Child and Human Development. <https://www.nichd.nih.gov/health/topics/uterine/conditioninfo/pages/symptoms.aspx>

² Richard-Davis, G. (2013). Uterine fibroid: the burden borne by African American women. *Journal of Women's Health*, 22(10): 793-794. DOI: 10.1089/jwh.2013.4597

³ *Int J Womens Health*. 2014; 6: 95-114. Published online 2014 Jan 29. doi: 10.2147/IJWH.S51083

⁴ Cain-Nielsen AH, Moriarty JP, Stewart EA, Borah BJ. Cost-effectiveness of uterine-preserving procedures for the treatment of uterine fibroid symptoms in the USA. *Journal of Comparative Effectiveness Research*. May 30 2014: 1-12.

⁵ Gupta JK, Sinha A, Lumsden MA, Hickey M. Uterine artery embolization for symptomatic uterine fibroids. *The Cochrane database of systematic reviews*. 2012;5:CD005073.

⁶ Scheurig-Muenkler C, Koesters C, Powerski MJ, Grieser C, Froeling V, Kroencke TJ. Clinical long-term outcome after uterine artery embolization: sustained symptom control and improvement of quality of life. *Journal of Vascular and Interventional Radiology Jun 2013;24(6):765-771*.

⁷ Toor SS, Jaber A, Macdonald DB, McInnes MD, Schweitzer ME, Rasuli P. Complication rates and effectiveness of uterine artery embolization in the treatment of symptomatic leiomyomas: a systematic review and meta-analysis. *American Journal of Roentgenology*. Nov 2012;199(5):1153-1163.

⁸ Abstract 106: "Nationwide analysis of hospital characteristics, demographics and cost of uterine fibroid embolization." S. Narayanan; A. Gonzalez; A. Echenique; P. Mohan; University of Miami Miller School of Medicine, Miami, FL. SIR Annual Scientific Meeting, March 4-9, 2017. - See more at: https://www.sirweb.org/advocacy-and-outreach/media/news-release-archive/news-release-uterine_fibroids_study#sthash.wxyjBAUT.dpuf

⁹ Minimally invasive, less expensive treatment for uterine fibroids underutilized. Press release; Society of Interventional Radiology, March 6, 2017.

SYNERGY REPORT

URONAV SYSTEM BOOSTS PROSTATE CANCER DIAGNOSIS, **Lessens Worry for Men**

New “Fusion Biopsy” system combines MRI, computer modeling and live ultrasound for faster, more accurate prostate cancer diagnosis

Prostate cancer is the most common cancer – and second leading cause of death – among U.S. men. Therefore, when positive digital rectal exams (DRE) and elevated PSA (prostate-specific antigen) levels raise clinical suspicion of cancer, a biopsy of prostate gland tissue is recommended. The prostate gland has historically been sampled by way of a blinded transrectal biopsy, which allows acquisition of tissue from various parts of the gland with no particular focus on any specific glandular region. These tissue samples are used to help diagnose and determine the grade, or Gleason score, of prostate cancer.

Because current biopsy methods aren't always efficient at finding actual cancer, they can lead to repeat and sometimes unnecessary biopsies. That's where magnetic resonance imaging (MRI) and the UroNav Fusion Biopsy System come in.

One of the primary advantages of prostate MRI is the ability to identify and accurately localize lesions with features of higher grade malignancies that require treatment. Radiologists, urologists and patients alike appreciate an improved ability to more efficiently diagnose lesions in need of treatment with fewer repeat or unnecessary biopsies. With a relatively high negative predictive value near 90%, some patients may avoid biopsy. Prostate MRI is also helpful for treatment planning in patients with positive biopsy results.

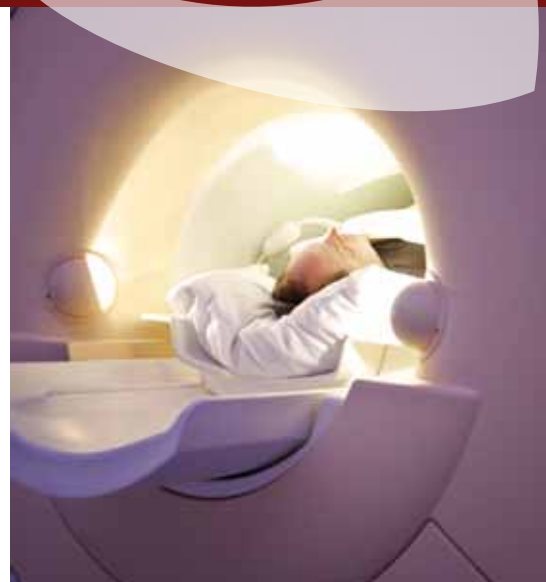
UroNav incorporates prostate image information from pre-biopsy MRI, computer-aided image enhancement and ultrasound-guided needle biopsy. This “fusion” of MRI and ultrasound results in targeted biopsies that are much better at detecting true cancer while avoiding the detection of low-risk or slow-growing cancer.

SRA radiologist Larry Schock, M.D., explained that before UroNav, physicians relied primarily upon transrectal ultrasound (TRUS) to visualize the prostate gland and sample multiple areas of the prostate to detect possible cancer cells. However, with TRUS biopsies, cancer can often go undetected.

“With the UroNav system, subspecialty radiologists and urologists work together to exploit the advantages of prostate MRI and ultrasound-guided biopsy techniques to more accurately detect cancers that require treatment,” said Schock. “Using this approach for our patients has produced a higher detection rate of clinically significant lesions compared to blind TRUS biopsy.”

Schock explained that radiologists appreciate the computer-aided, 3-D imaging capabilities supporting UroNav that improve diagnosis, detection and treatment

(continued on inside)



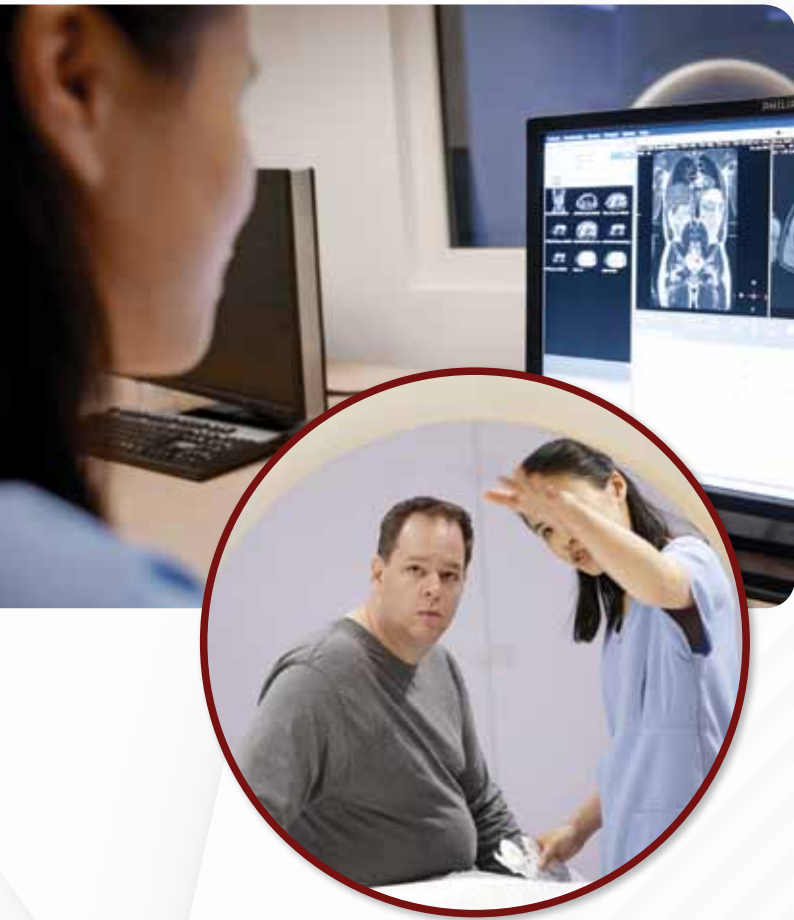In this issue

**Spotlight on Pediatrics:
Welcoming Our New Subspecialty
Trained Pediatric Radiologists
Tatum Johnson, M.D., and
Michael Nasser, M.D.**

**Uterine Fibroid Embolization Available
in Houston as Minimally Invasive
Alternative to Total Hysterectomy**

**New “Fusion Biopsy” System
Boosts Prostate Cancer Diagnosis,
Lessens Worry for Men**

**Community Involvement 2017:
SRA Clay Shoot Participation
Supports Life Flight Program**




PROSTATE CANCER: *(continued)*

planning, and male patients appreciate a quicker, more certain diagnosis with fewer repeat or unnecessary biopsies.

If a suspicious lesion is identified using prostate MRI, our radiologists use the DynaCAD workstation to precisely localize and label the abnormality within a 3-dimensional MR model of the gland. Urologists can then perform targeted biopsies using live ultrasound and the labeled 3-D MRI model to sample suspicious areas within the gland.

The UroNav procedure is being performed by urologists at several Memorial Hermann Hospitals. Diagnostic prostate MRI takes about 30 to 45 minutes in the hospital or imaging center. The UroNav fusion biopsy is an outpatient procedure that takes about 15 to 20 minutes and can be performed very shortly after the diagnostic MRI.

UroNav is generally recommended for patients with a PI-RADS (prostate scoring system) score of 3 or higher, negative prior transrectal ultrasound (TRUS) biopsies with a continued elevated or rising PSA, or positive digital rectal examination with a negative TRUS biopsy.

For more information on UroNav and other minimally invasive procedures, visit the SRA Vascular and Interventional services page. Physician practices interested in learning more about prostate MRI and UroNav should contact the Synergy Radiology team at 713-621-1103. 


SRA CLAY SHOOT PARTICIPATION SUPPORTS LIFE FLIGHT PROGRAM



For the third consecutive year, Synergy Radiology Associates is proud to have participated in the Memorial Hermann Heroes in Health Sporting Clay Shoot. This year, Synergy's contribution consisted of a team of four radiologists and the sponsorship of two on-course stations. We were also able to present two door prizes to the attendees during the awards ceremony.

The Heroes in Health Sporting Clay Shoot raises funds to benefit the Memorial Hermann Life Flight program. Life Flight operates as a hospital-based, non-profit organization, and it relies entirely on community support and fundraising efforts such as the Clay Shoot. Houston's only hospital-based air medical service, Life Flight serves Houston and surrounding communities, including Harris County, southeast Texas and part of western Louisiana.

"These sorts of events offer Synergy Radiology the opportunity to reinforce our commitment to the success of the Memorial Hermann system and to showcase our alignment with shared values," said SRA President Walid Adham, M.D.,

More than 300 people participated in this year's Heroes in Health Sporting Clay Shoot. To learn more about Heroes in Health, visit <http://heroesinhealth.memorialhermann.org>. For more information about the Life Flight program or to donate, visit www.memorialhermann.org/lifeflight/donate. 

PHYSICIAN SPOTLIGHT

SRA Welcomes New Pediatric Radiologists

At Synergy Radiology, our small patients are a big responsibility. Our subspecialty trained pediatric radiologists know that children are a unique and special patient population. In this edition of the Synergy Report, we spotlight our two pediatric radiologists, Tatum Johnson, M.D., and Michael Nasser, M.D.

“Every child is a precious gift and deserves the best start in life. Having an opportunity to make a difference in their lives is fulfilling.”

— Tatum Johnson, M.D.

Tatum Johnson, M.D.

Dr. Johnson particularly enjoys working with families and consulting with pediatricians to help solve unique and challenging pediatric cases.

“I love the technology and reviewing the images,” said Johnson. “As a radiologist, I am able to help patients in a unique way, incorporating information from many different sources and then doing my best to ‘solve the case.’”



She noted that pediatric patients present with different problems than adults.

“Pediatric patients may present with congenital diseases, for example, which are fascinating from an embryologic and developmental point of view,” said Dr. Johnson.

Dr. Johnson is a board-certified radiologist with a certificate of added qualification in pediatric radiology. She graduated from Louisiana State University School of Medicine in Shreveport and completed her residency at Dartmouth-Hitchcock Medical Center in Lebanon, New Hampshire. Dr. Johnson conducted her pediatric radiology fellowship at St. Louis Children’s Hospital-Washington University School of Medicine. 📍

Pediatric radiologists read a diverse array of radiographic studies, encompassing different imaging modalities. The added subspecialty training and expertise offers referring physicians and their patients an added measure of diagnostic confidence. 📍

“The best part of working with children is that you can help make significant changes in their lives.”

— Michael Nasser, M.D.

Michael Nasser, M.D.

As a radiology resident, Dr. Nasser rotated through Boston Children’s Hospital department of radiology for one month. One of the senior attending radiologists, Carlo Buonomo, M.D, made a significant and lasting impression on him.



“He is a well-known pediatric radiologist, and he remains one of my greatest teachers in medicine,” explained Dr. Nasser. “His influence led me to pediatric radiology. I also focused on fluoroscopy, which was his specialty. When I returned to my residency, I focused predominantly on pediatric radiology; I knew then that I would apply for a fellowship in this specialty.”

Dr. Nasser applied to and was accepted for a fellowship at Cincinnati Children’s Hospital Medical Center (CCHMC). He spent 10 years at CCHMC as an attending radiologist prior to joining the SRA team.

“It’s important to remember that pediatric patients are not just little adults. Children have unique concerns and illnesses that are distinctly different from adults,” observed Nasser.

He said his experience working with children has helped him appreciate their unique set of requirements and understand that pathologies common among young patients can be very different from those that plague older patients.

“As a new member of Synergy Radiology Associates, I hope to bring my passion for pediatric radiology to Houston and to all of our patients,” said Nasser.

Dr. Nasser is board-certified with a certificate of added qualification in pediatric radiology. A graduate of Virginia Commonwealth University Medical School in Richmond, he completed his residency at the University of Massachusetts Memorial Medical Center and earned his fellowship in pediatric radiology at CCHMC.

Although he enjoys many hobbies, Dr. Nasser said things have changed since he and his wife welcomed son, James, into the world. That is the “hobby” that now joyously occupies most of his time outside of work. 📍

For more information, or to consult with one of our radiologists, please contact us at 713-621-1103.